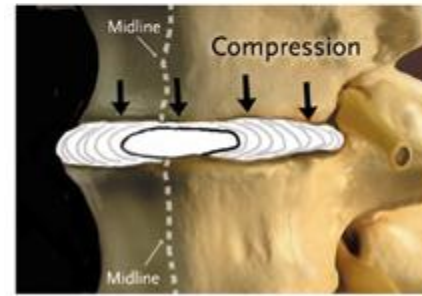
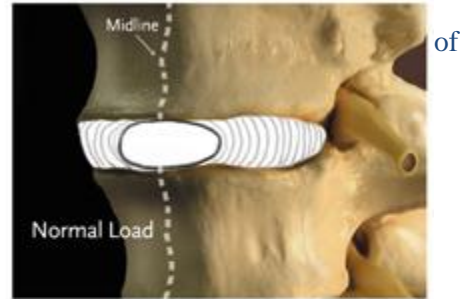
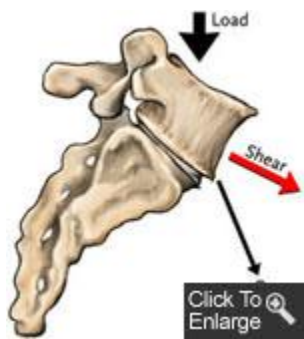



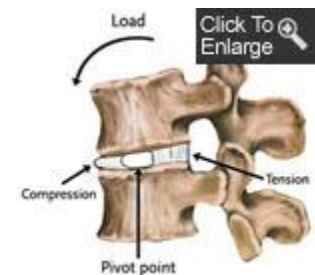
Mechanical Disorders: Degenerative Disc Disease

Degenerative disc disease (DDD) is part of the natural process of growing older. Unfortunately, as we age, our inter-vertebral discs lose their flexibility, elasticity, and shock absorbing characteristics. The ligaments that surround the disc called the annulus fibrosis, become brittle and they are more easily torn. At the same time, the soft gel-like center of the disc, called the nucleus pulposus, starts to dry out and shrink. The combination of damage to the inter-vertebral discs, the development of bone spurs, and a gradual thickening of the ligaments that support the spine can all contribute to degenerative arthritis of the lumbar spine.



Degenerative disc disease is certainly to happen to everyone. However, not everyone who has degenerative changes in their lumbar spine has pain. Many people who have "normal" backs have MRIs that show disc herniations, degenerative changes, and narrowed spinal canals. Every patient is different, and it is important to realize that not everyone develops symptoms as a result of degenerative disc disease.

When degenerative disc disease becomes painful or symptomatic, it can cause several different symptoms, including back pain, leg pain, and weakness that are due to compression of the nerve roots. These symptoms are caused by the fact that worn out discs are a source of pain because they do not function as well as they once did, and as they shrink, the space available for the nerve roots also shrinks.



As the discs between the inter-vertebral bodies start to wear out, the entire lumbar spine becomes less flexible. As a result, people complain of back pain and stiffness, especially towards the end of the day.

Symptoms

The most common symptom of degenerative disc disease is back pain. When DDD causes compression of the nerve roots, the pain often radiates down the legs or into the feet, and may be associated with numbness and tingling. In severe cases of lumbar DDD, where there is evidence of nerve root

compression, individuals may experience symptoms of sciatica and back pain, and sometimes even lower extremity weakness.

Diagnosis

The diagnosis of degenerative disc disease begins with a complete physical examination of the body, with special attention paid to the back and lower extremities. Your doctor will examine your back for flexibility, range of motion, and the presence of certain signs that suggest that your nerve roots are being affected by degenerative changes in your back. This often involves testing the strength of your muscles and your reflexes to make sure that they are still working normally. You will often be asked to fill out a diagram that asks you where your symptoms of pain, numbness, tingling and weakness are occurring.



A routine set of x-rays is also usually ordered when a patient with back pain goes to see a doctor. If degenerative disc disease is present, the x-rays will often show a narrowing of the spaces between the vertebral bodies, which indicates that the disc has become very thin or has collapsed. Bone spurs begin to form around the edges of the vertebral bodies and also around the edges of the facet joints in the spine. These bone spurs can be seen on an x-ray, where they are called osteophytes. As the disc collapses and bone spurs form, the space available for the nerve roots starts to shrink. The nerve roots exit the spinal canal through a bony tunnel called the neuro-foramen, and it is at this point that the nerve roots are especially vulnerable to compression.

In many situations, doctors will order a MRI or a CT scan (CAT scan) in order to evaluate the degenerative changes in the lumbar spine more completely. A MRI scan is very useful for determining where disc herniations have occurred and where the nerve roots are being compressed. A CT scan is often used to evaluate the bony anatomy in the spine, which can show how much space is available for the nerve roots and within the neuro-foramen and spinal canal.

Treatment

Your doctor will be able to discuss with you what your diagnosis means in terms of treatment options. For most people who do not have evidence of nerve root compression with muscle weakness, the first line of therapy includes non-steroidal anti-inflammatory drugs and physical therapy.

In those patients in whom these conservative measures don not improve their pain, a reasonable option is a series of three or four epidural steroid injections, which tend to work in the vast majority of patients. Surgery is offered only after all other options have failed to adequately relieve the symptoms of pain, numbness and weakness over a significant period of time.

680 North Lake Shore Drive, Suite # 830
Chicago, IL. 60611

Phone: (888) 951-6471 Fax: (888) 961-6471 Clinical Coordinator: (312) 961-6471
admin@rivernorthpmc.com

www.rivernorthpmc.com www.ibji-gw.com